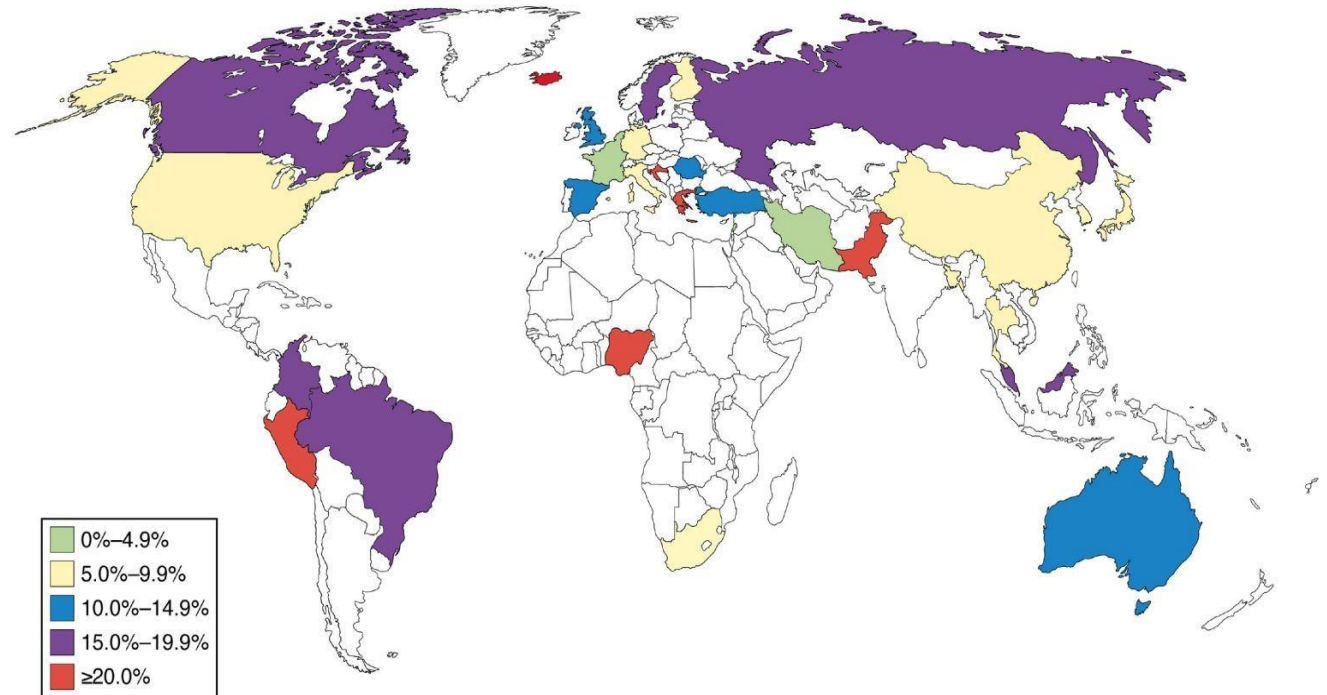


Post-infectious IBS

G. Boeckxstaens
KU Leuven, University Hospital Leuven
Leuven, Belgium

Food allergy, food sensitivity, food intolerance and ... IBS?

- IBS is a symptom-based diagnosis
- 4-10 % of Western population
- Changes in stool consistency or frequency, discomfort and/or pain
- No detectable abnormalities on endoscopy, radiological imaging or lab tests
- Limited insight in pathophysiology – disappointing treatment
- Heterogenous patient population
- **Common in all patients = abdominal pain**

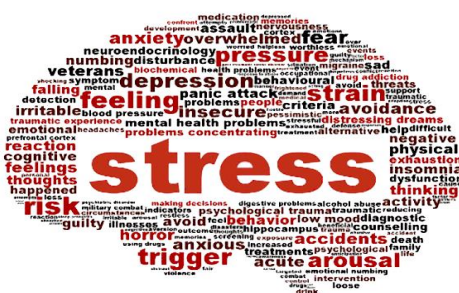


What are the triggers leading to mast cell activation in IBS?

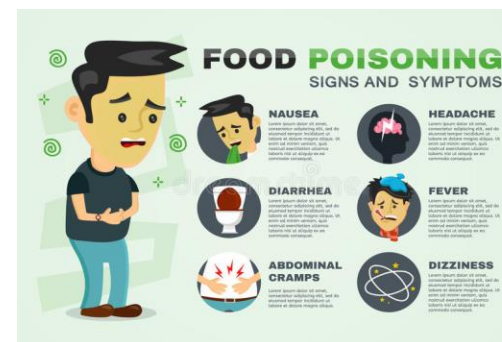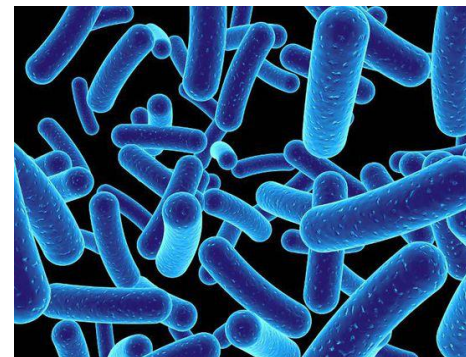
Food



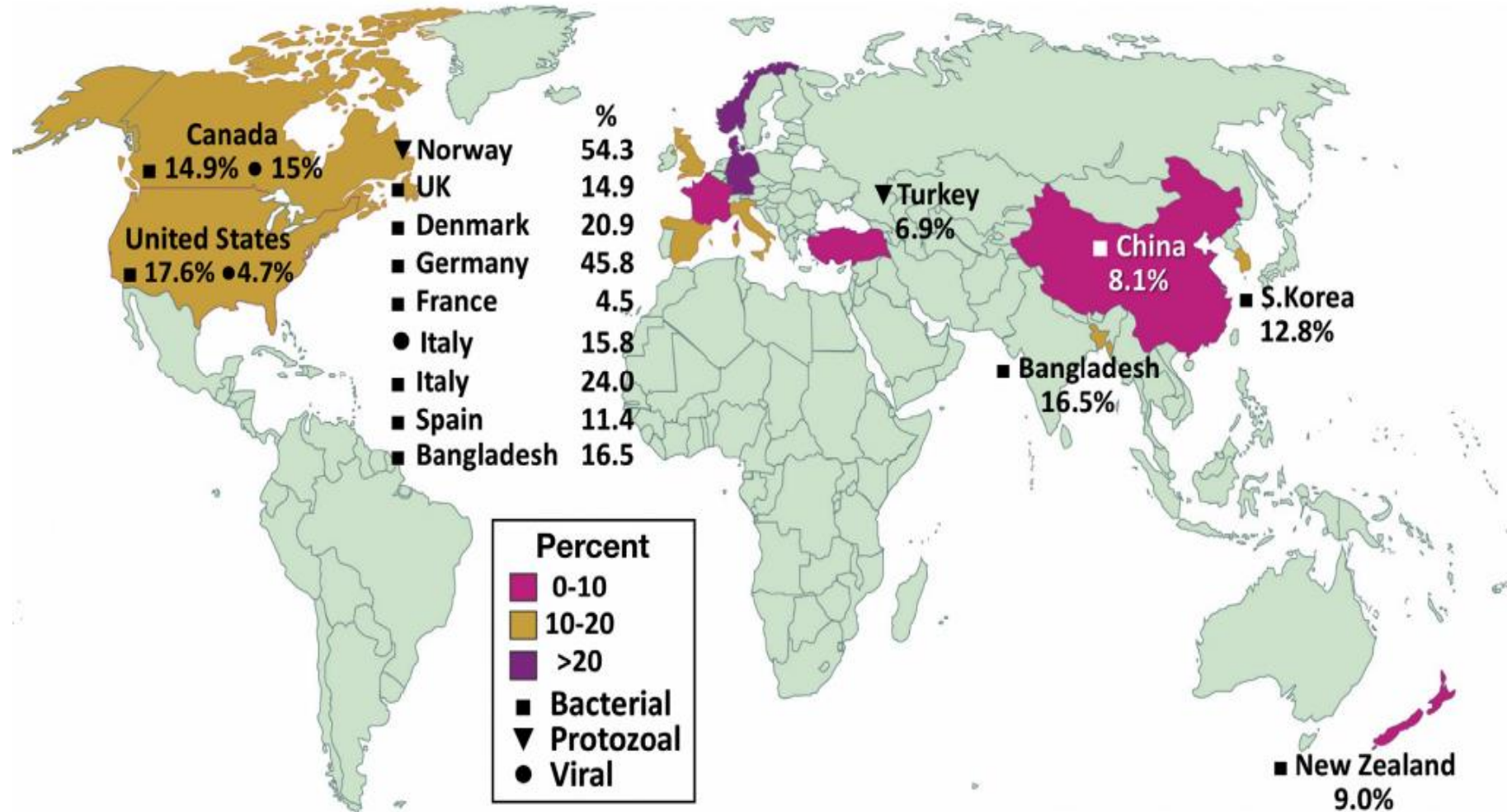
Stress



Infection

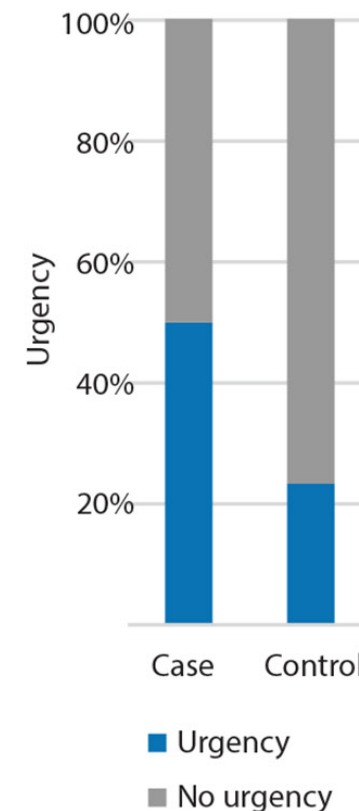
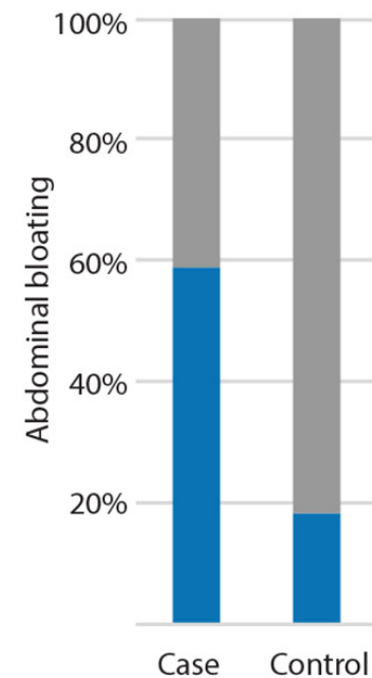
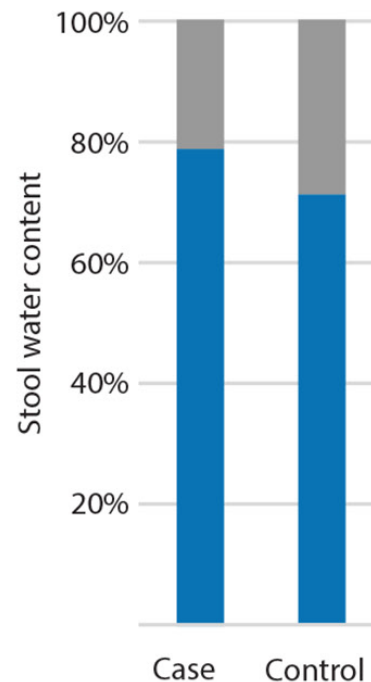
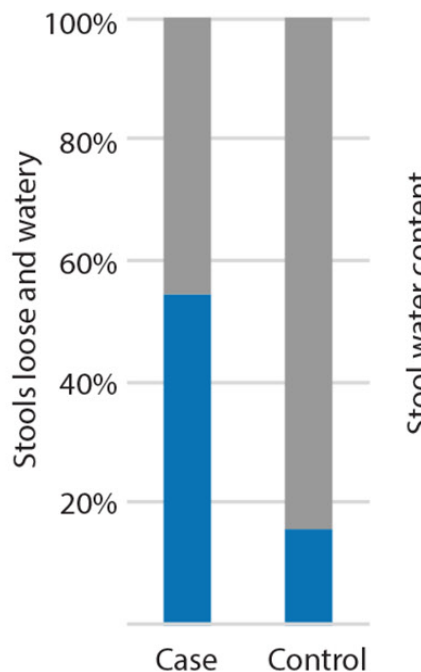
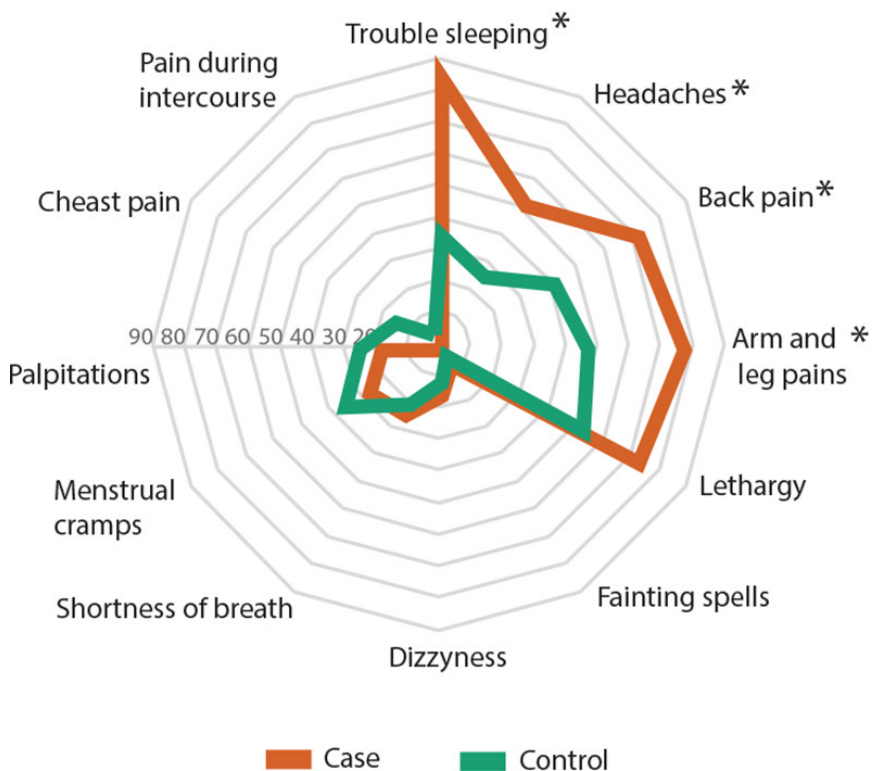


Infectious gastroenteritis as a risk factor to develop IBS



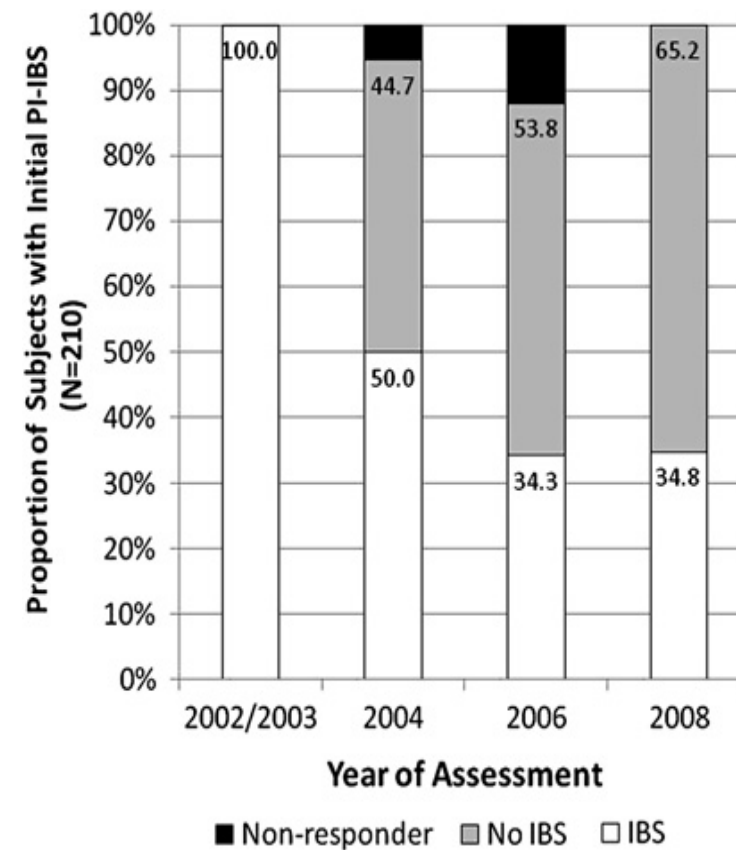
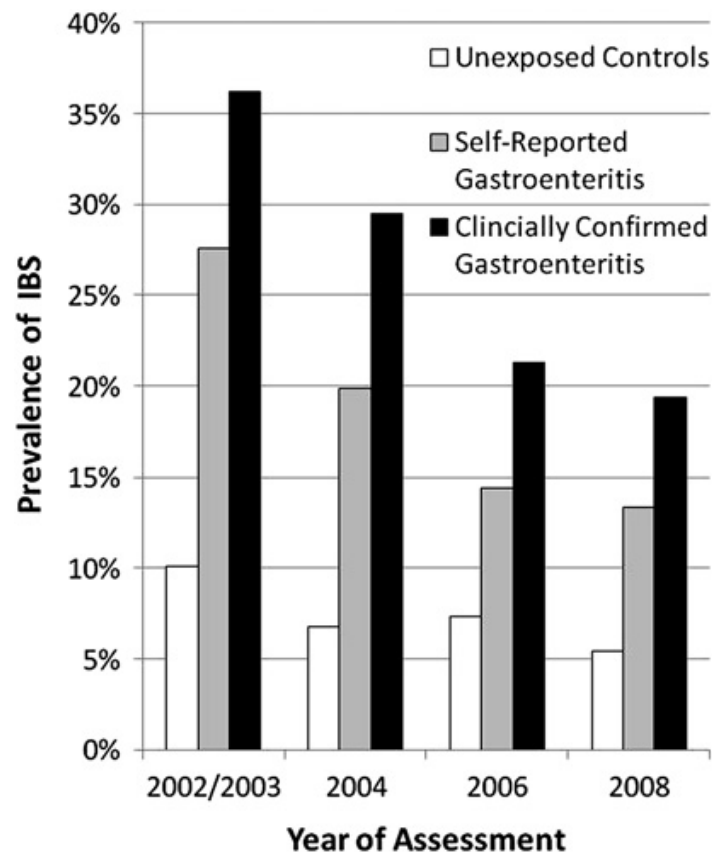
Campylobacter-induced gastrointestinal complaints 3 months following infection

99 subjects infected with *Campylobacter jejuni*: 22 had persistent GI symptoms after 3 months – 45% fulfilled Rome III criteria for IBS



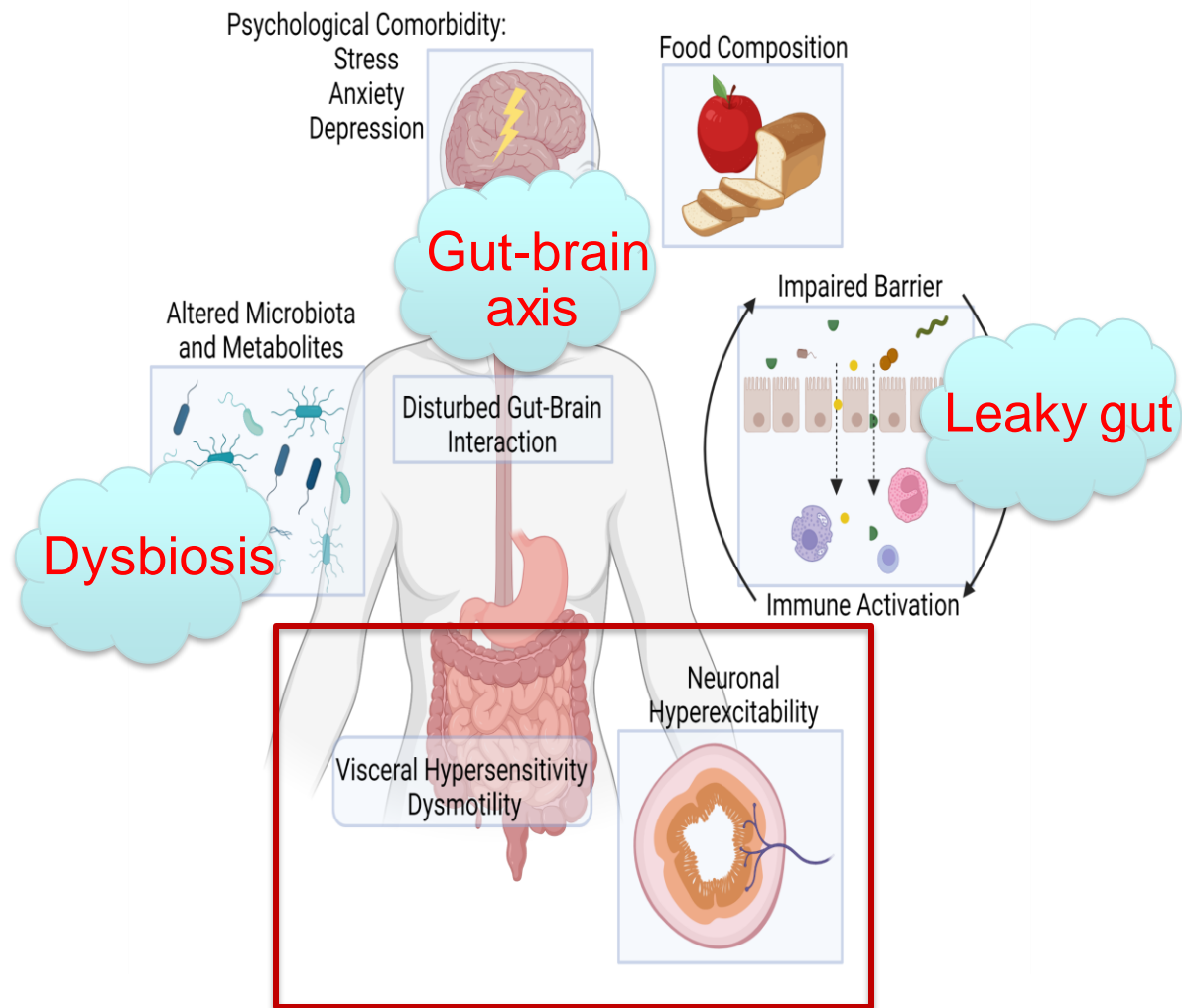
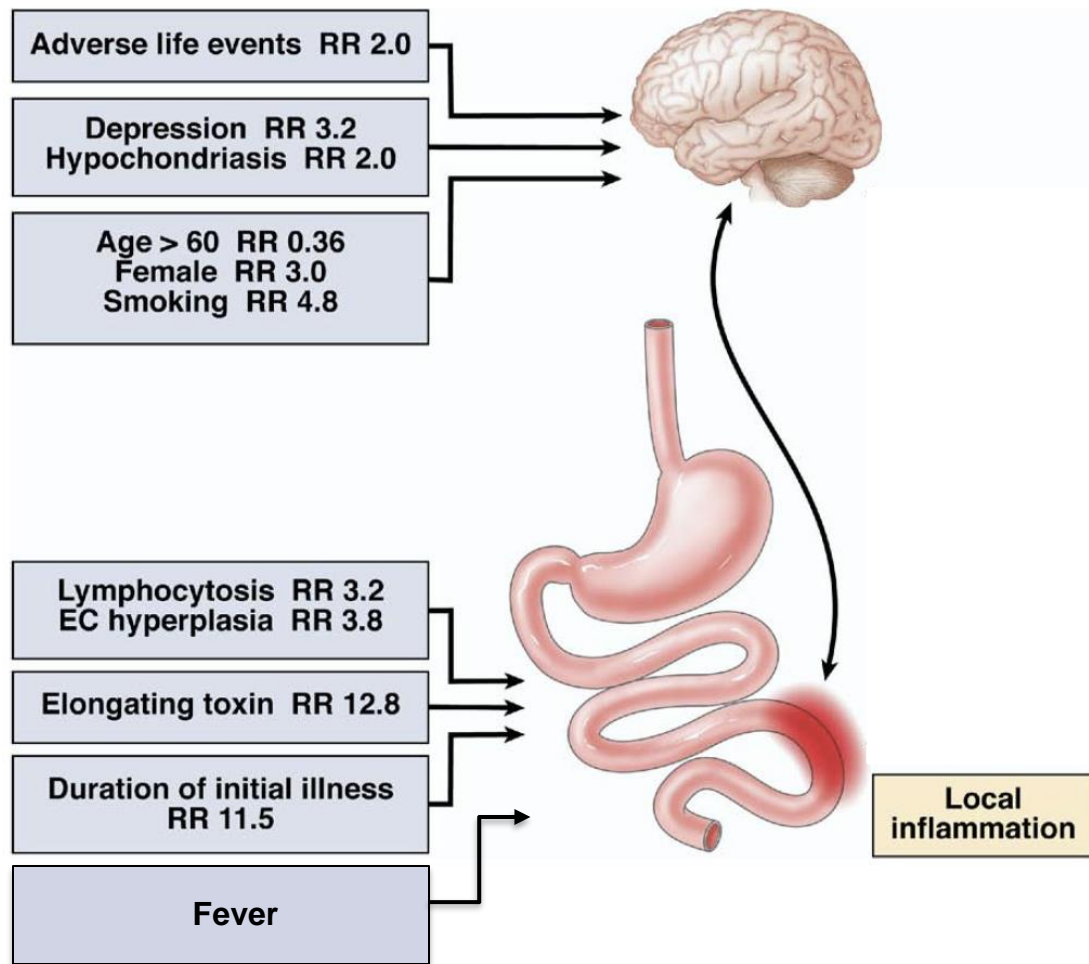
Symptoms of post-infectious IBS can persist for years

- Walkerton, Ontario, Canada:
- in 2000, heavy rainfall washed livestock fecal residue into drinking water supply
- Contamination with *E. coli*, *Campylobacter jejuni* and other pathogens affecting at least 2300 locals (6 died)
- Large cohort was followed during 8 years

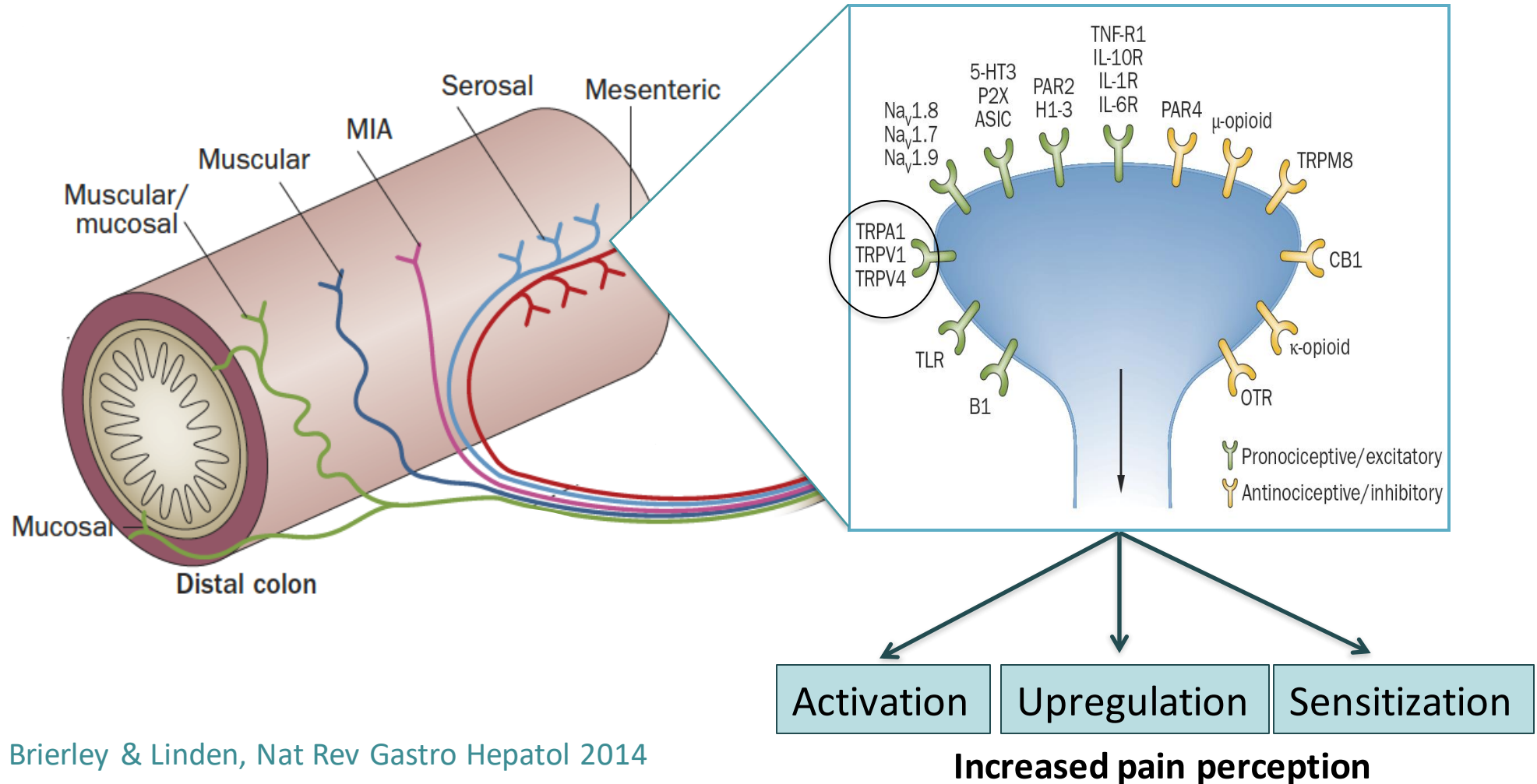


Marshall et al., Gut 2010

Risks factors of PI-IBS and mechanisms underlying abnormal pain signaling



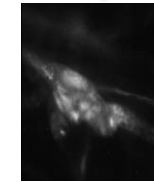
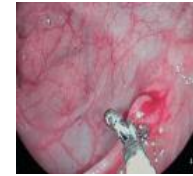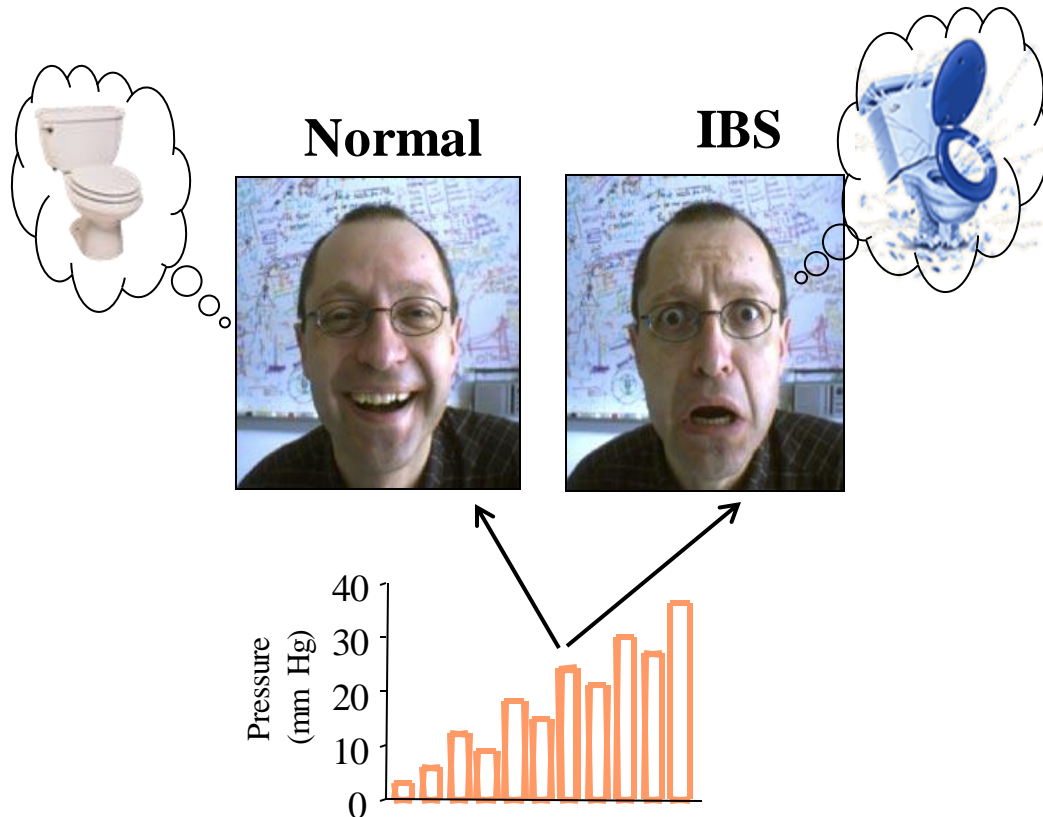
Abdominal pain is transmitted via extrinsic afferent nerve fibers innervating the intestine



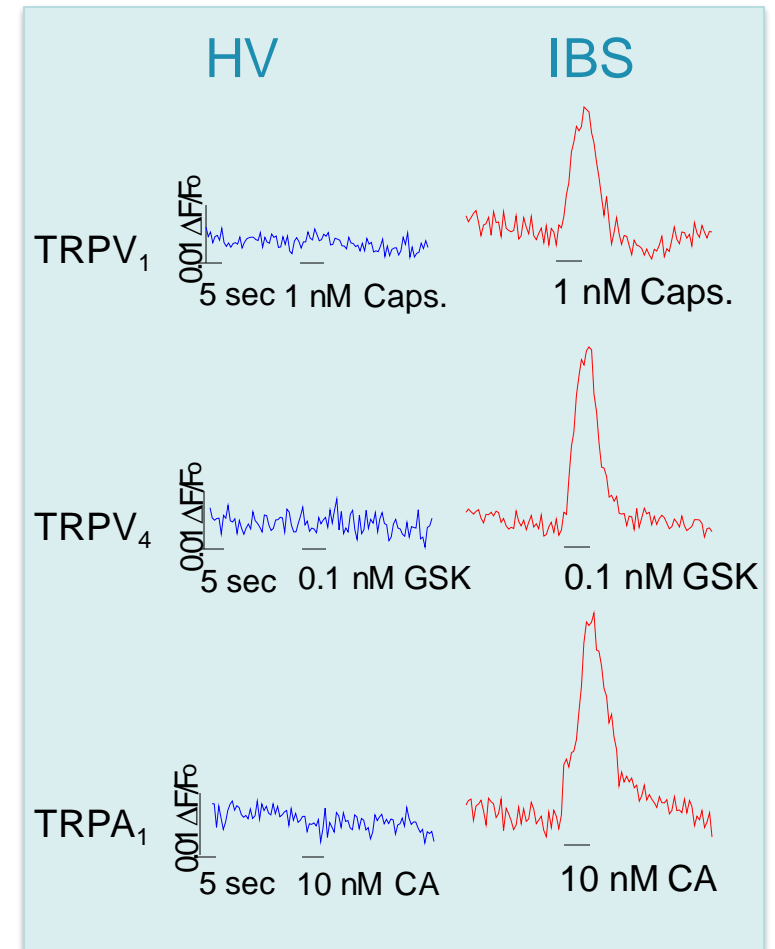
What do we know about the pathophysiology of IBS?

Abnormal pain signaling

Increased sensitivity to colonic distention

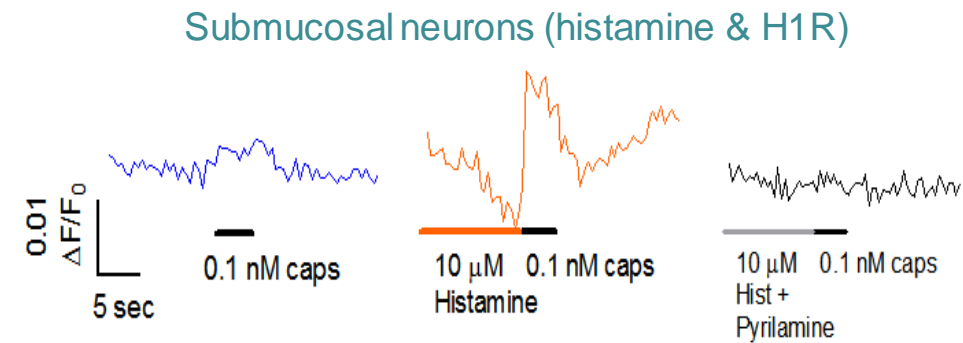
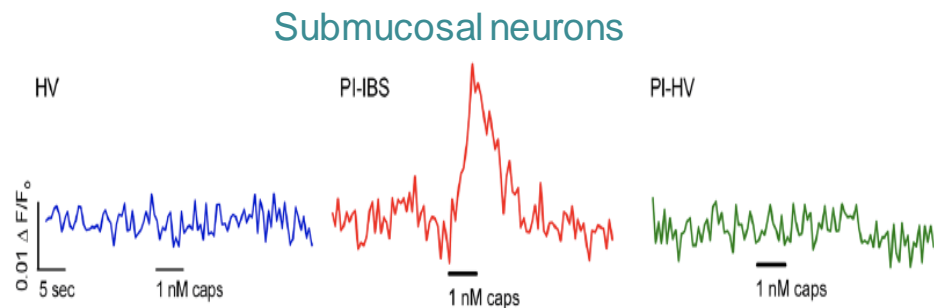


Cirillo et al., Gut 2013

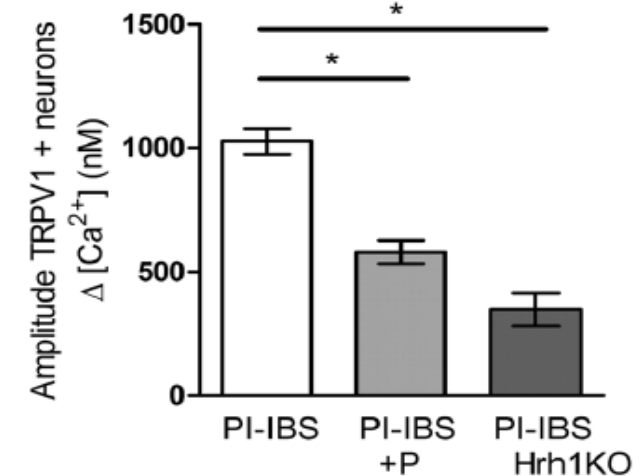
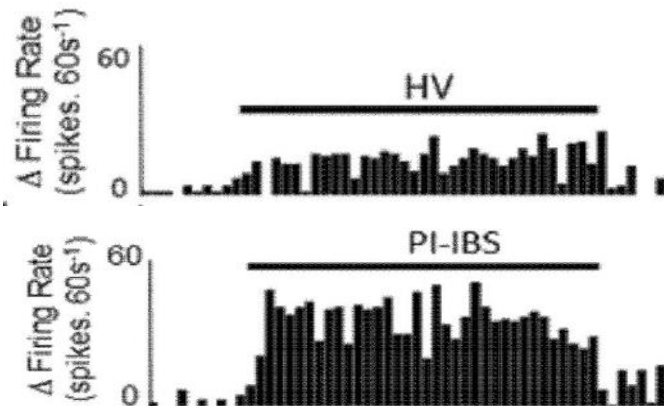
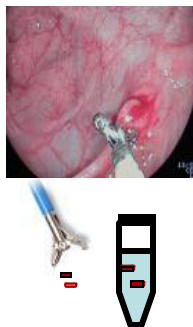

Role of histamine in increased excitability of submucosal neurons and visceral afferents in PI-IBS

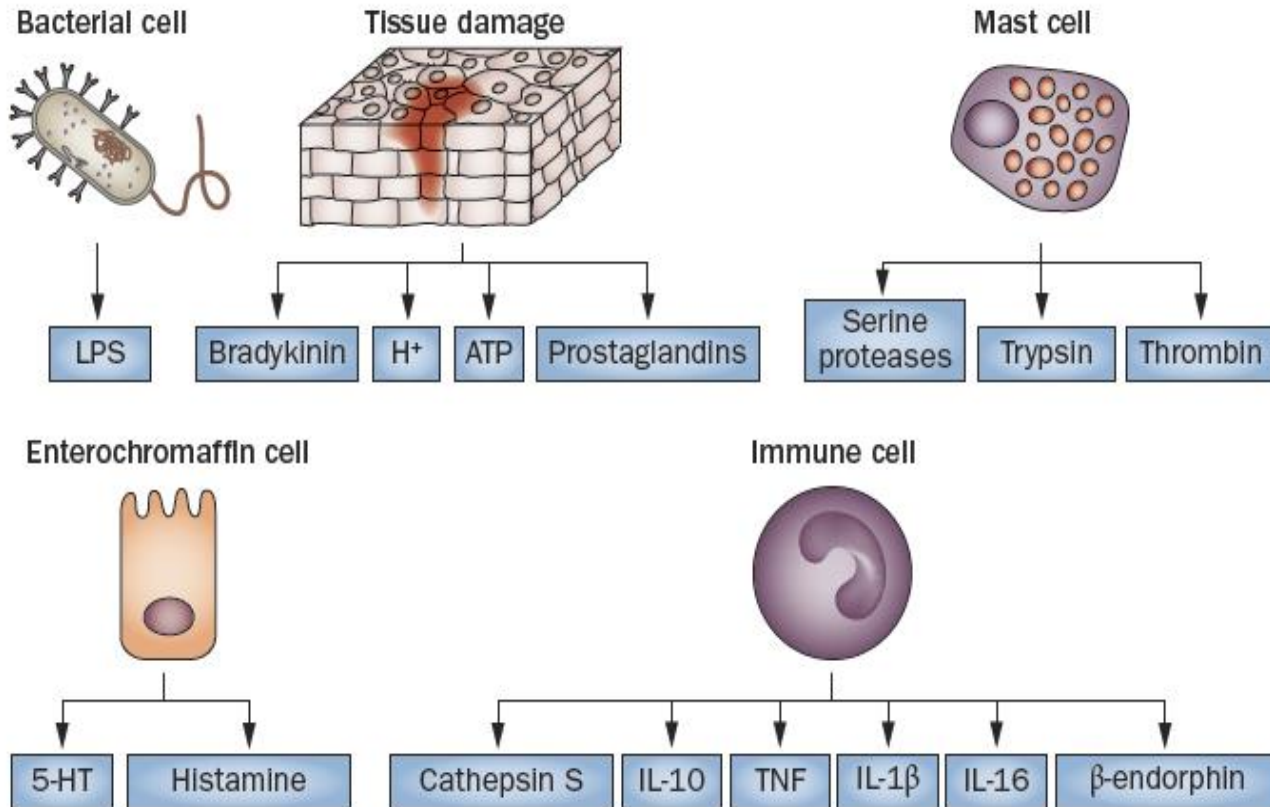
Contamination of drinking water in 2 Belgian villages (Hemiksem and Schelle) – rectal biopsies collected after 2 years from controls, infected non-IBS and PI-IBS



Biopsy supernatant on murine visceral afferents

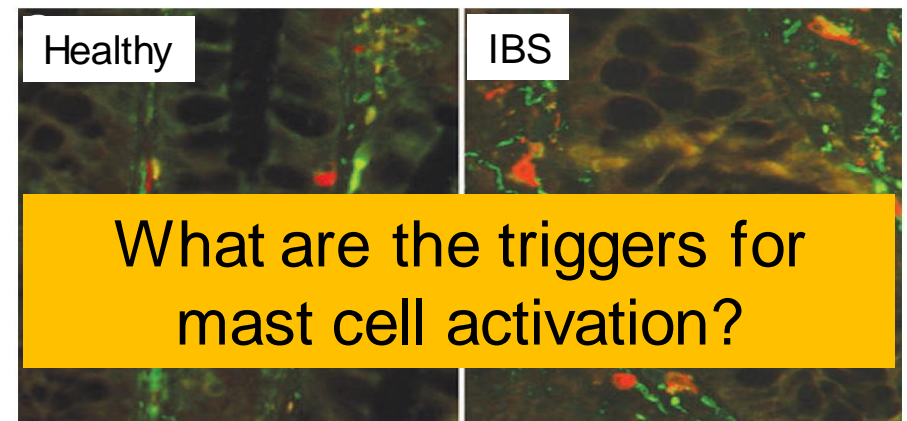


Immune cells and mediators potentially interacting with afferent nerves

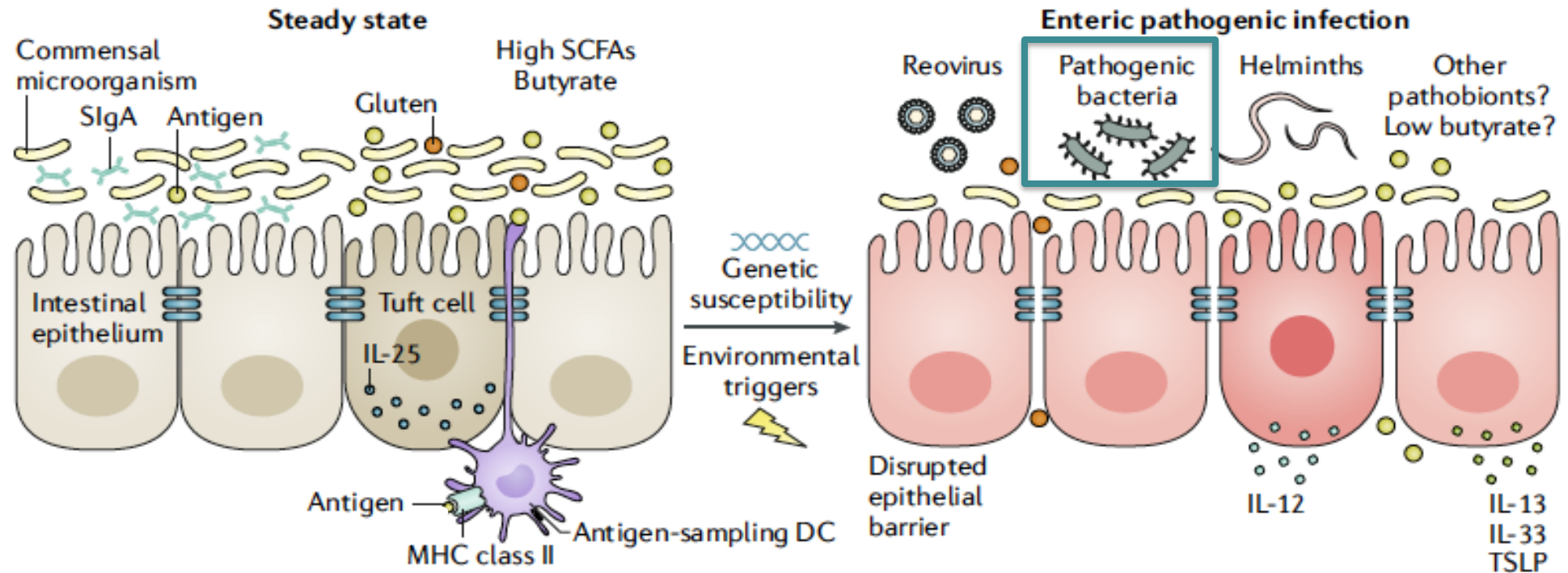


Brierley & Linden, Nat Rev Gastroenterol Hepatol 2014

- Neural activation blocked by antagonist of serotonin, histamine, proteases
- Increased numbers of mast cells in intestinal biopsies
- Increased release of histamine and proteases in supernatant of IBS biopsies



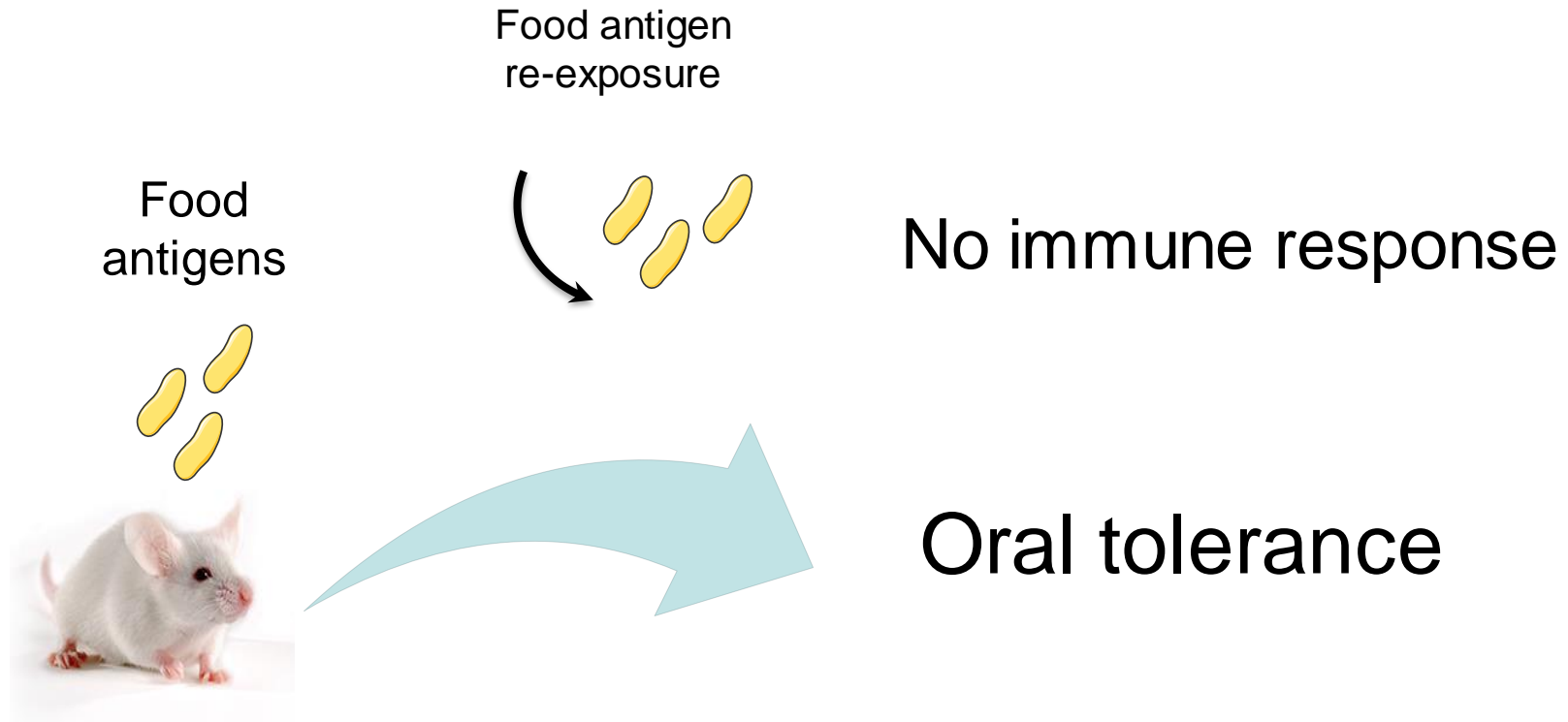
Loss of tolerance to food antigens in IBS?



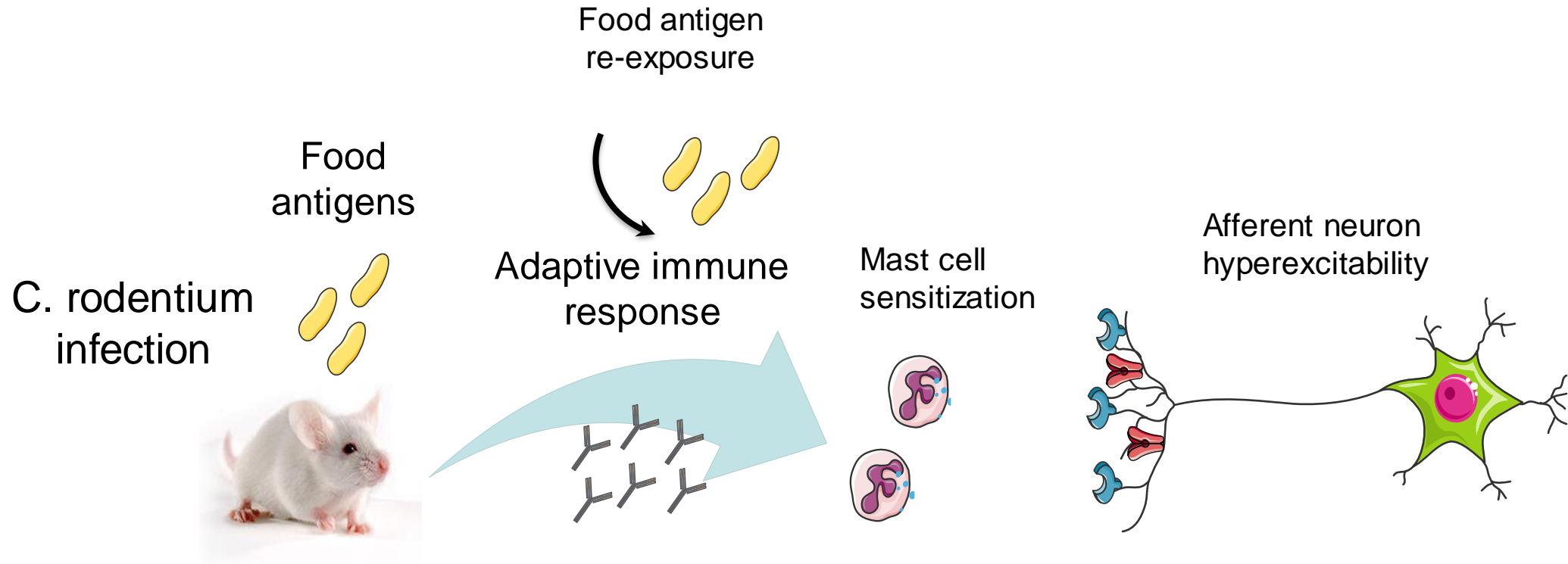
Oral tolerance to gluten or other dietary antigens

Coeliac disease (Th1)
Food allergy (Th2)

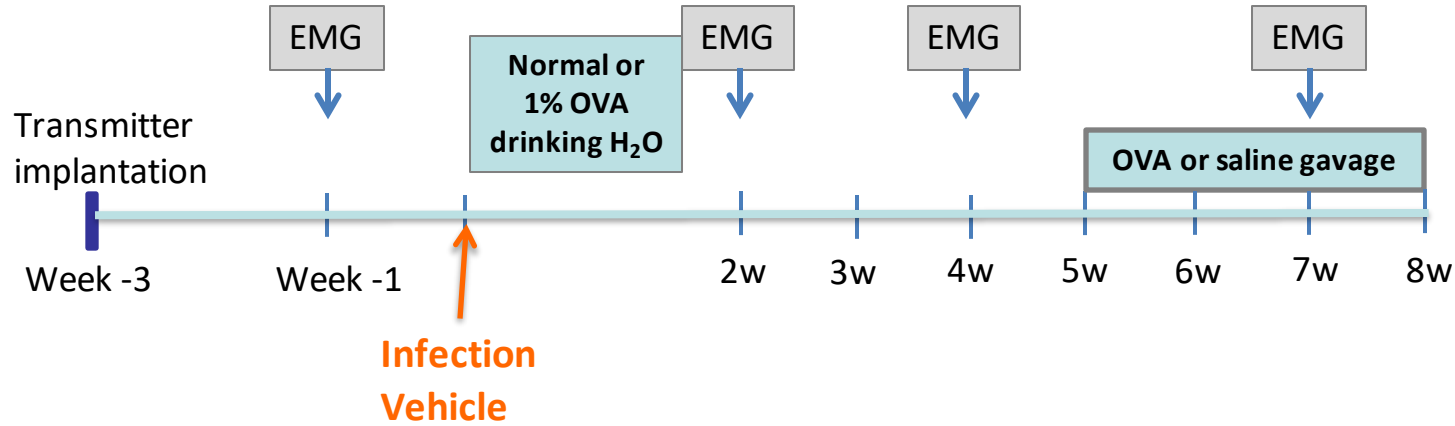
Aberrant immune response triggered against food antigens during gastrointestinal infection?



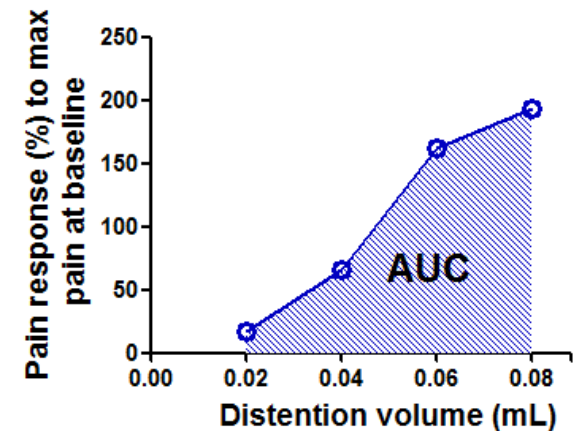
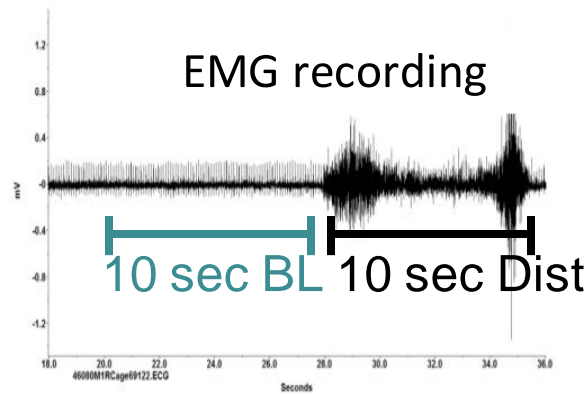
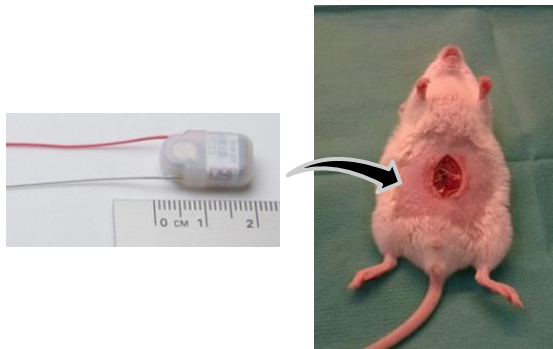
Aberrant immune response triggered against food antigens during gastrointestinal infection?



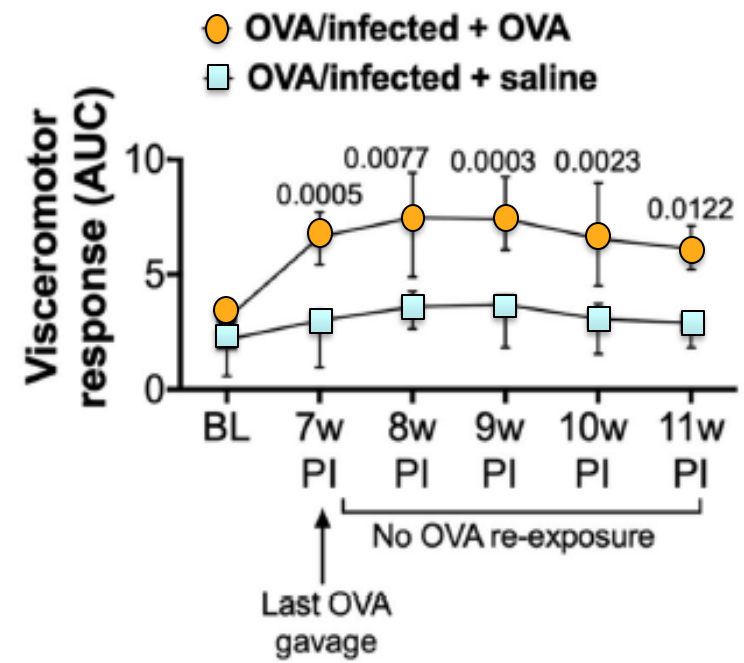
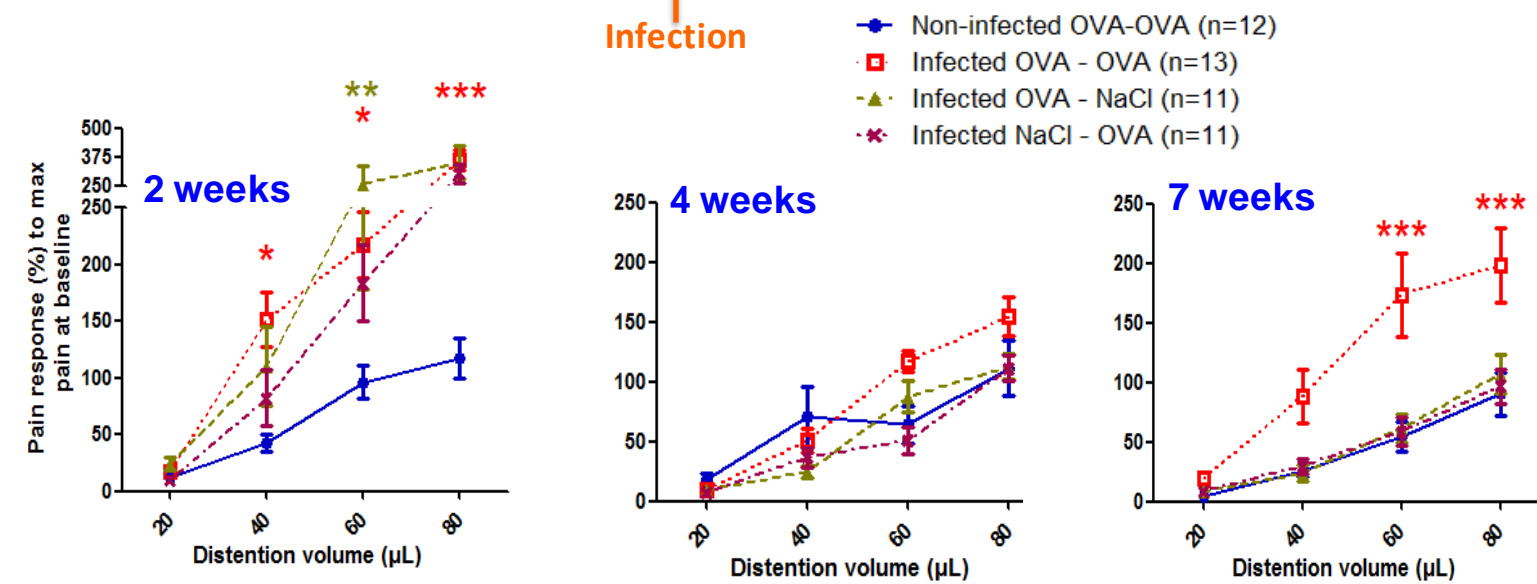
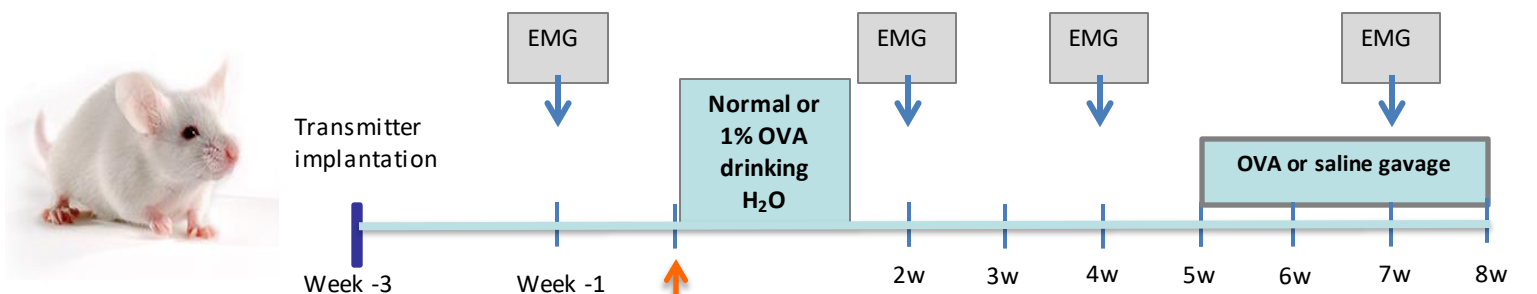
Is loss of oral tolerance to OVA triggering abnormal pain signaling in response to OVA re-exposure?



- Non-infected OVA-OVA (n=12)
- Infected OVA - OVA (n=13)
- ▲ Infected OVA - NaCl (n=11)
- * Infected NaCl - OVA (n=11)

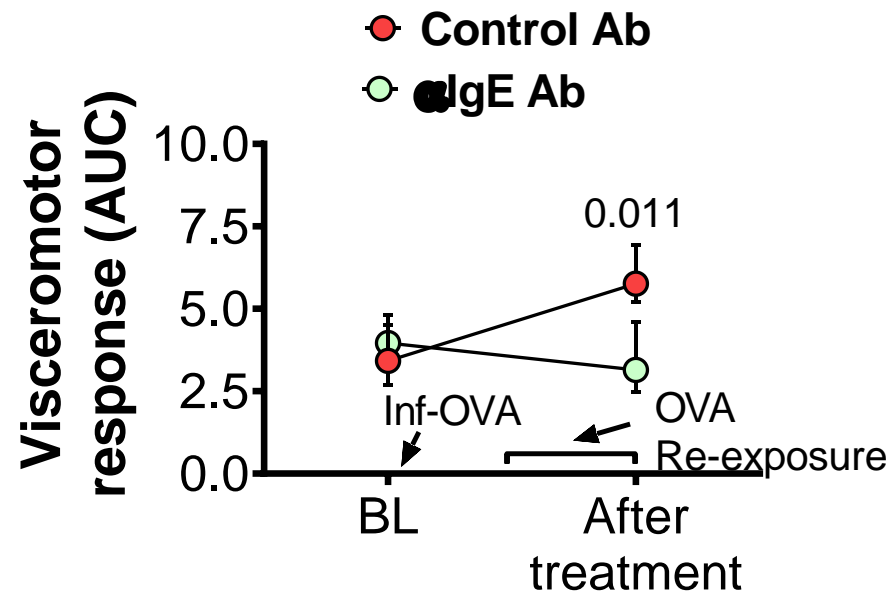
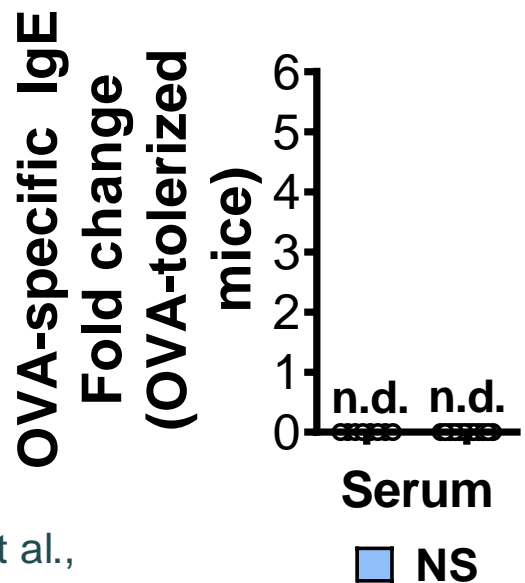
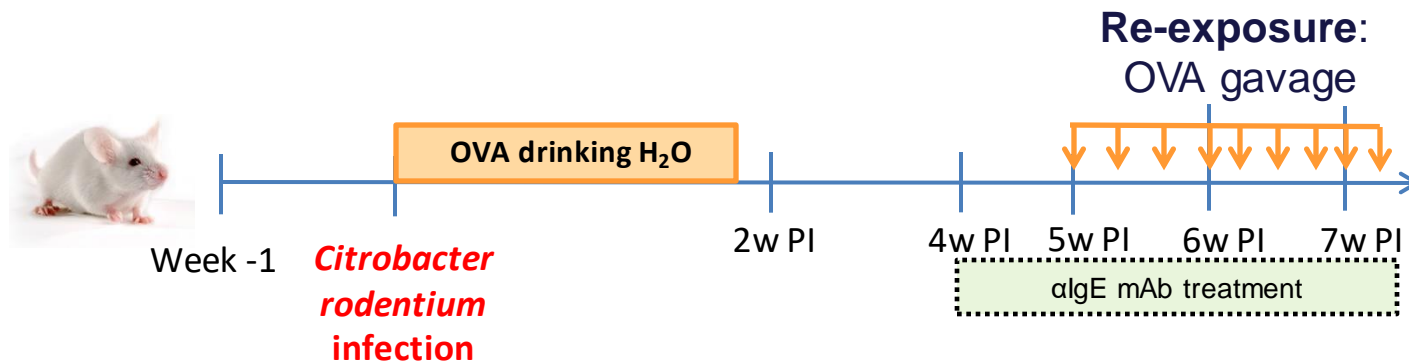


Long-lasting visceral hypersensitivity evoked by re-exposure to OVA following infection with *C. rodentium*

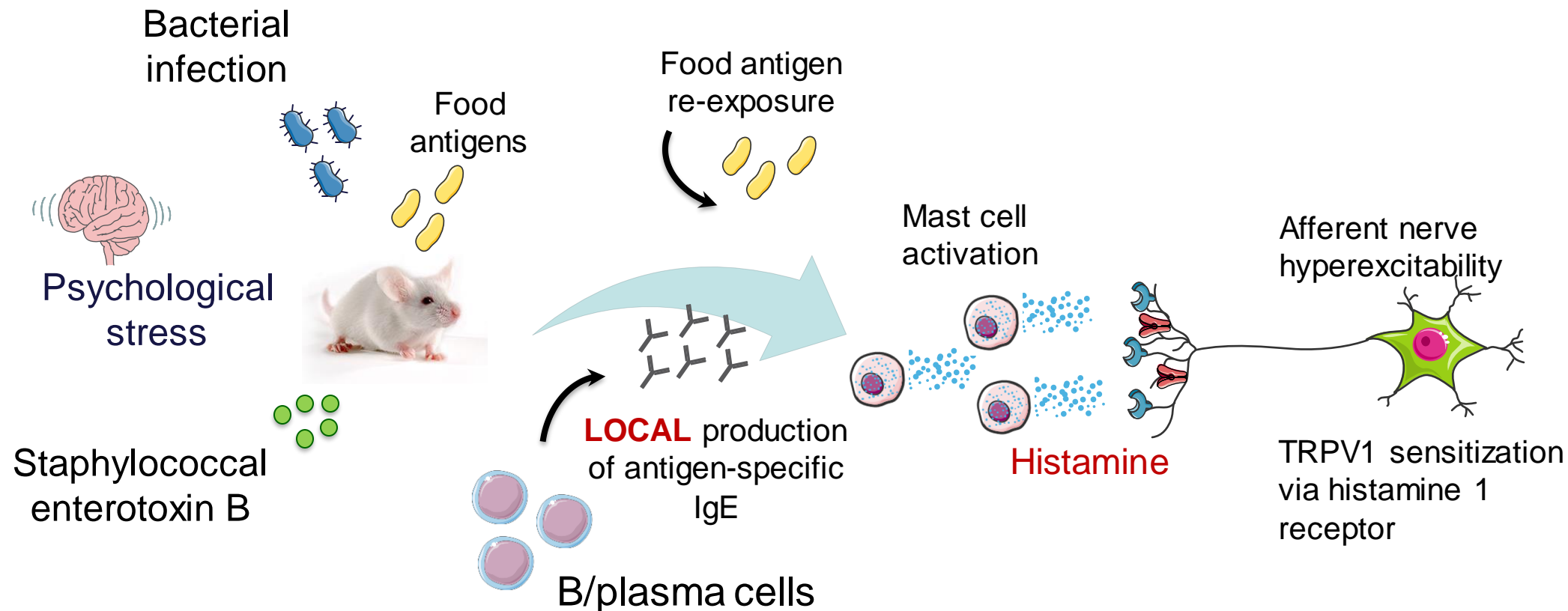


No VHS in mast cell deficient mice

Blockade of OVA-specific IgE with monoclonal IgE antibody prevents visceral hypersensitivity



Food-induced IgE-mediated mast cell activation as underlying mechanism of visceral hypersensitivity (abdominal pain)



Mucosal reaction to food antigen injection in IBS patients

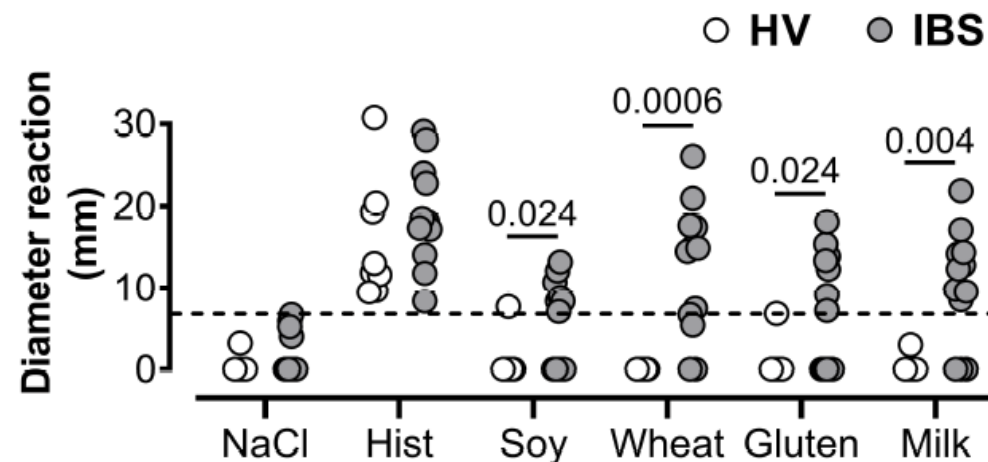
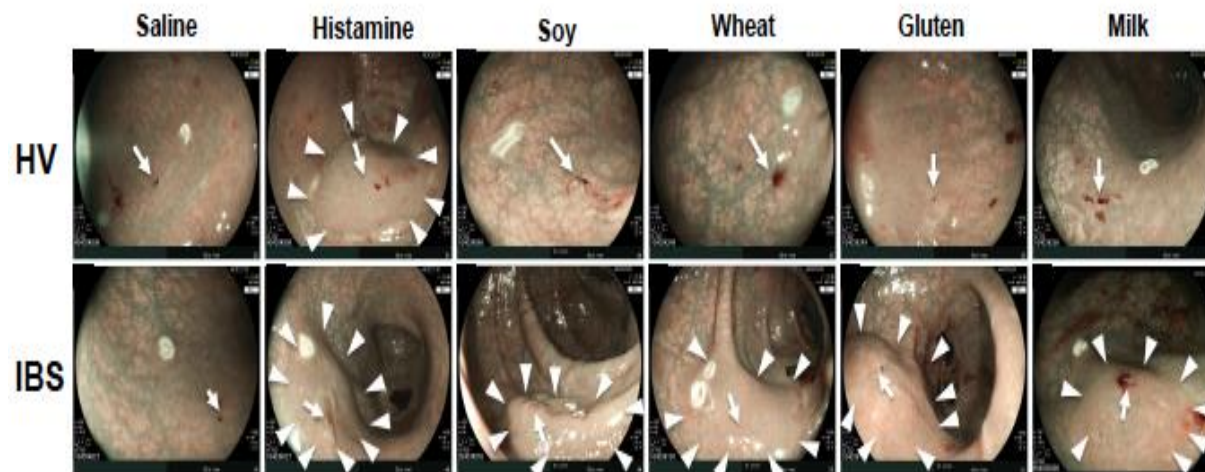
- IBS patients (neg skin prick test and neg serum IgE levels) vs healthy controls
- Food antigens (wheat, gluten, milk, soy) injected into the mucosa to trigger MC activation
- Development of oedema and visibility of vasculature was scored after 12 minutes



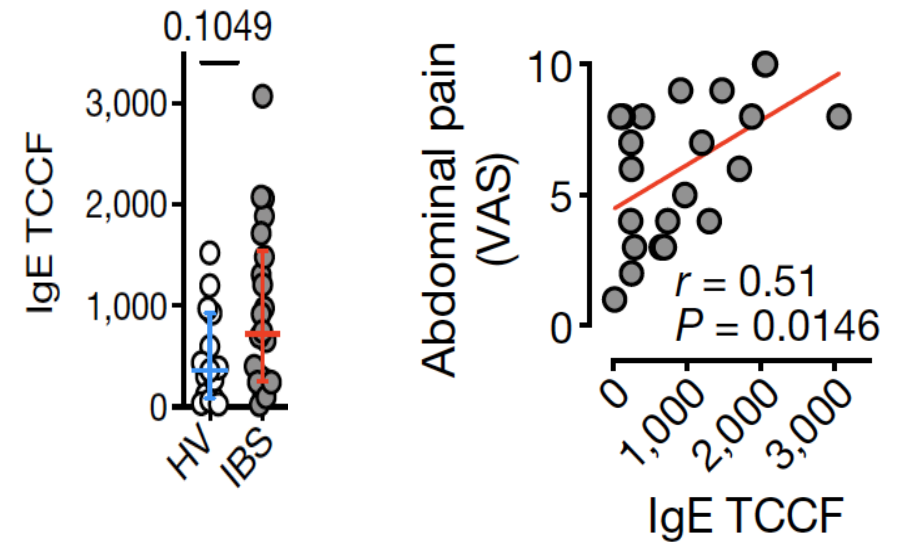
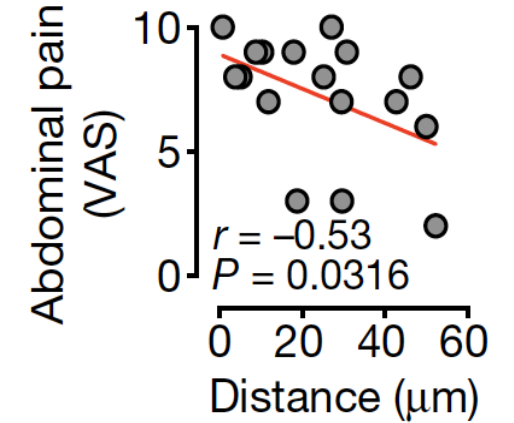
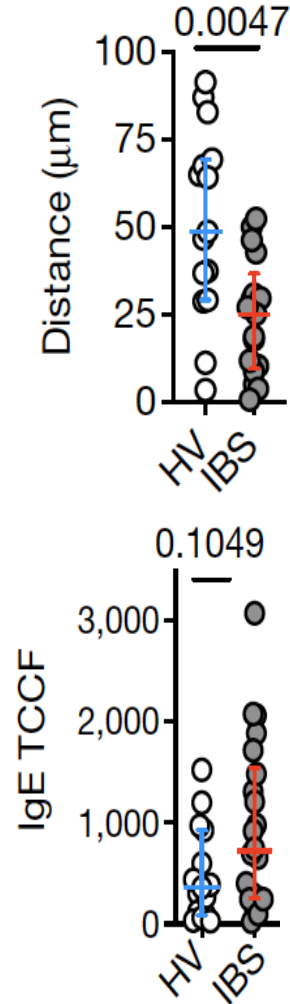
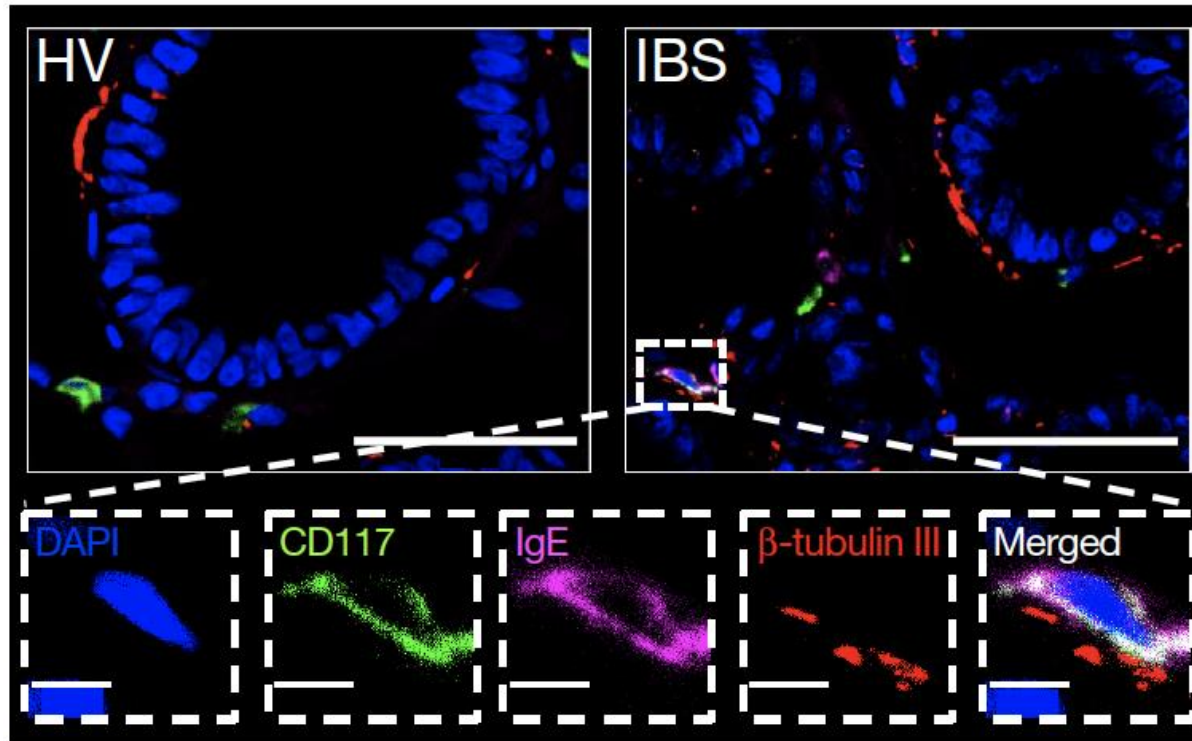
Antigen
injection

Mucosal reaction to food antigen injection in IBS patients

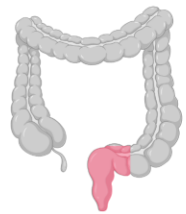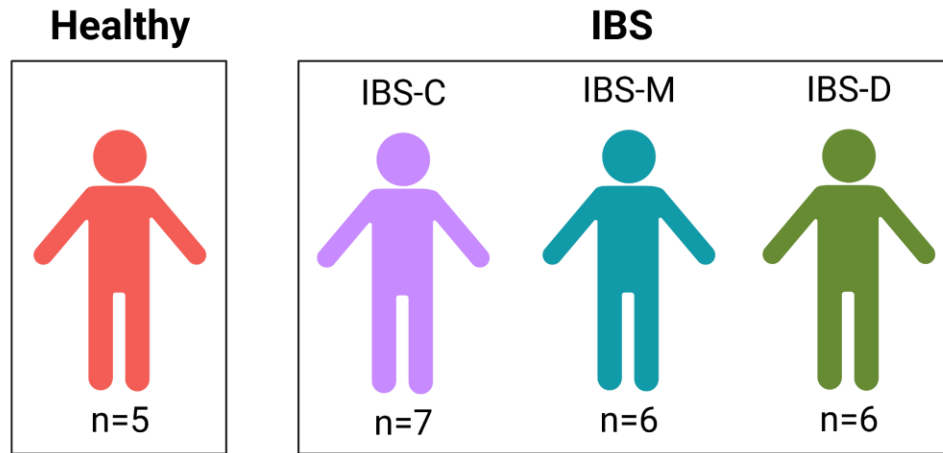
- IBS patients (neg skin prick test and neg serum IgE levels) vs healthy controls
- Food antigens (wheat, gluten, milk, soy) injected into the mucosa to trigger MC activation
- Development of oedema and visibility of vasculature was scored after 12 minutes



IgE-mediated mast cell activation in IBS patients



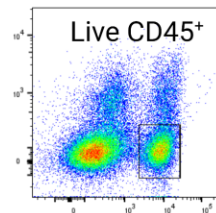
scRNAseq of rectal biopsies collected from healthy volunteers and IBS patients



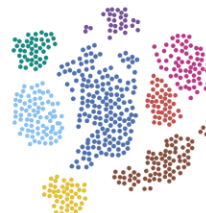Rectal biopsies



Single cell suspension



FACS sorting



10x single cell RNAseq

Antibody secreting cells



HV

IBS

IGHA1

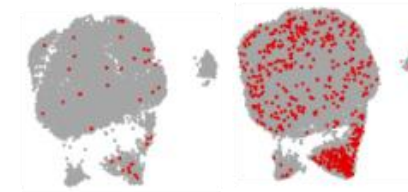

IGHG1

HV

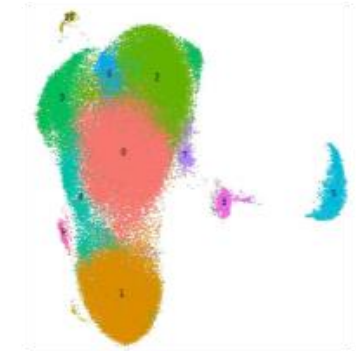
IBS

IGHE

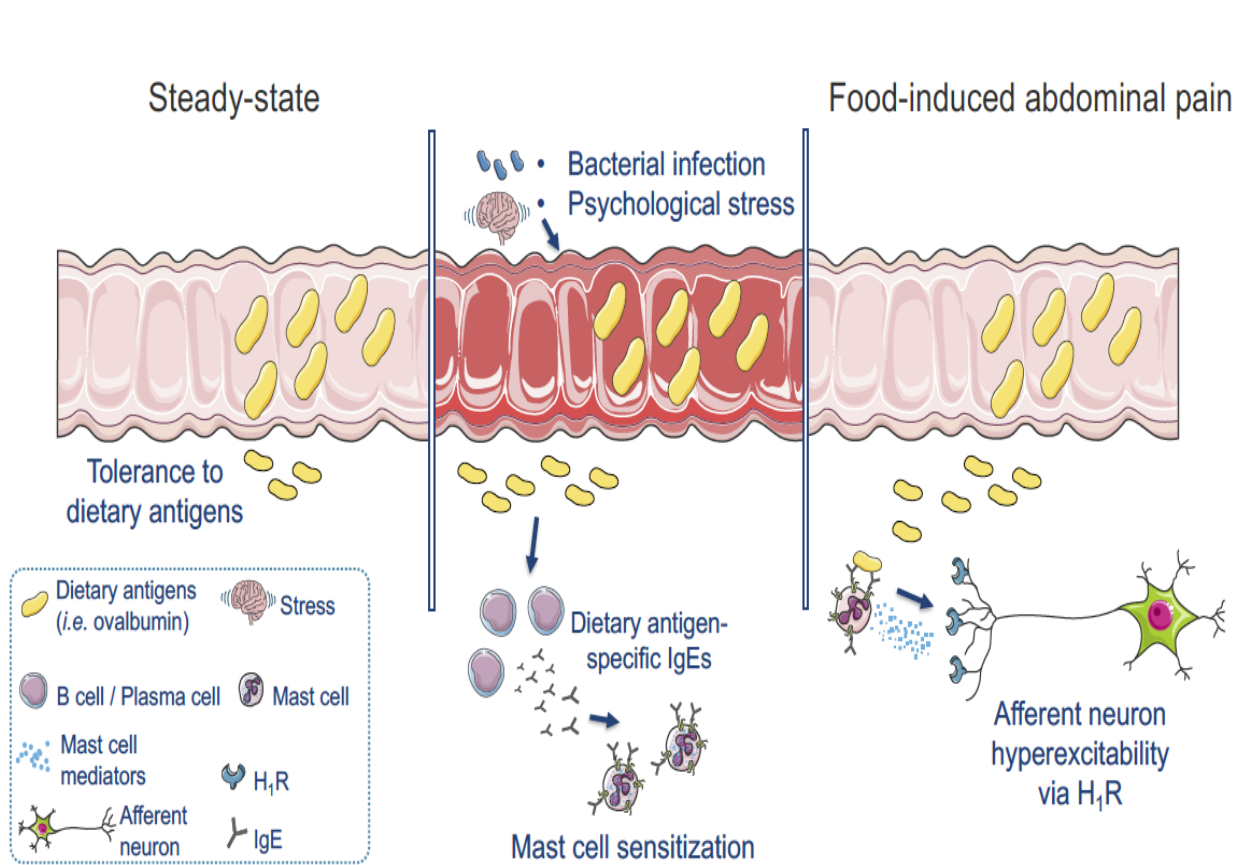


IGHE

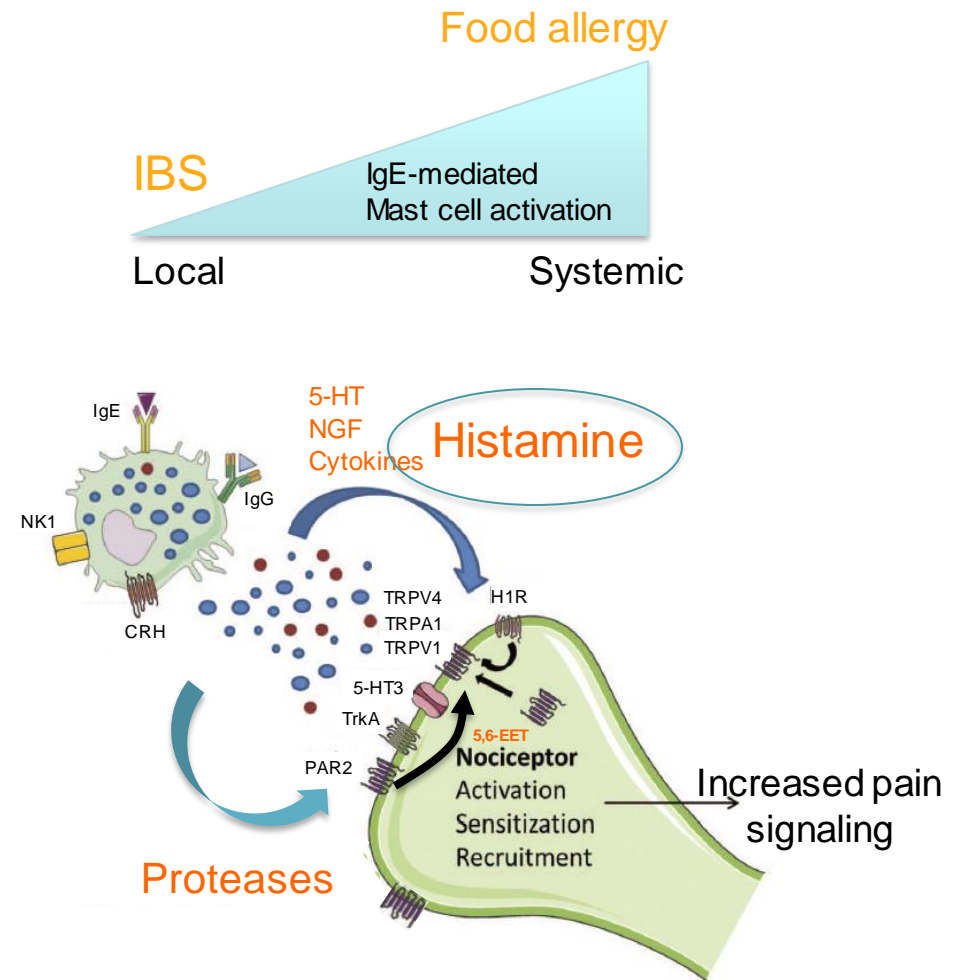
B cells



Mast cells as potential target for treatment of IBS



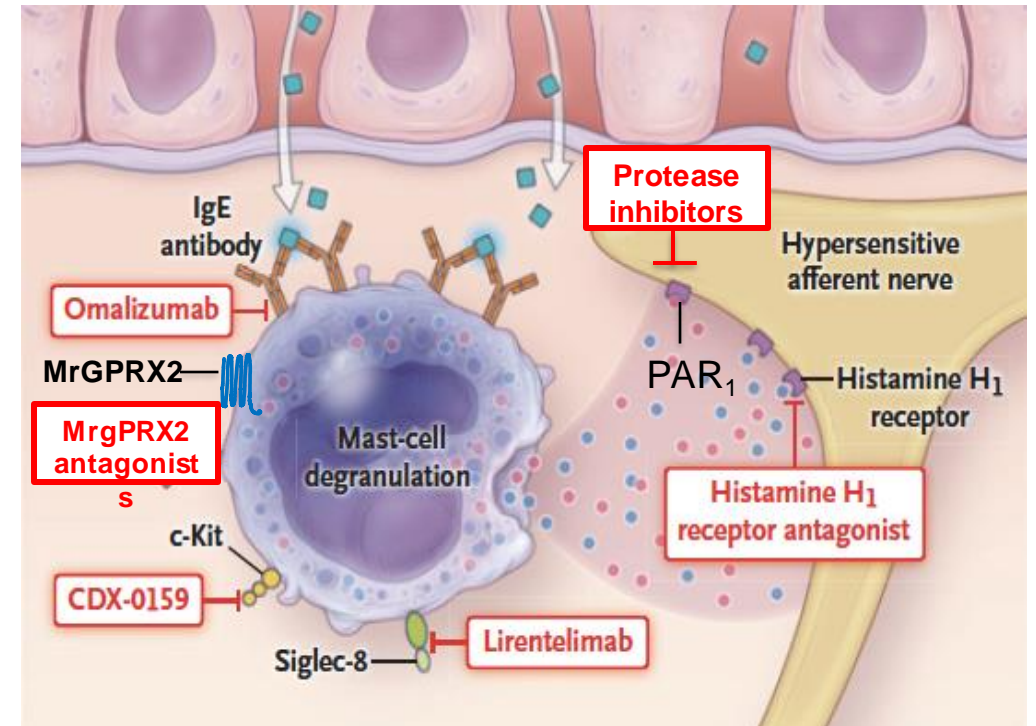
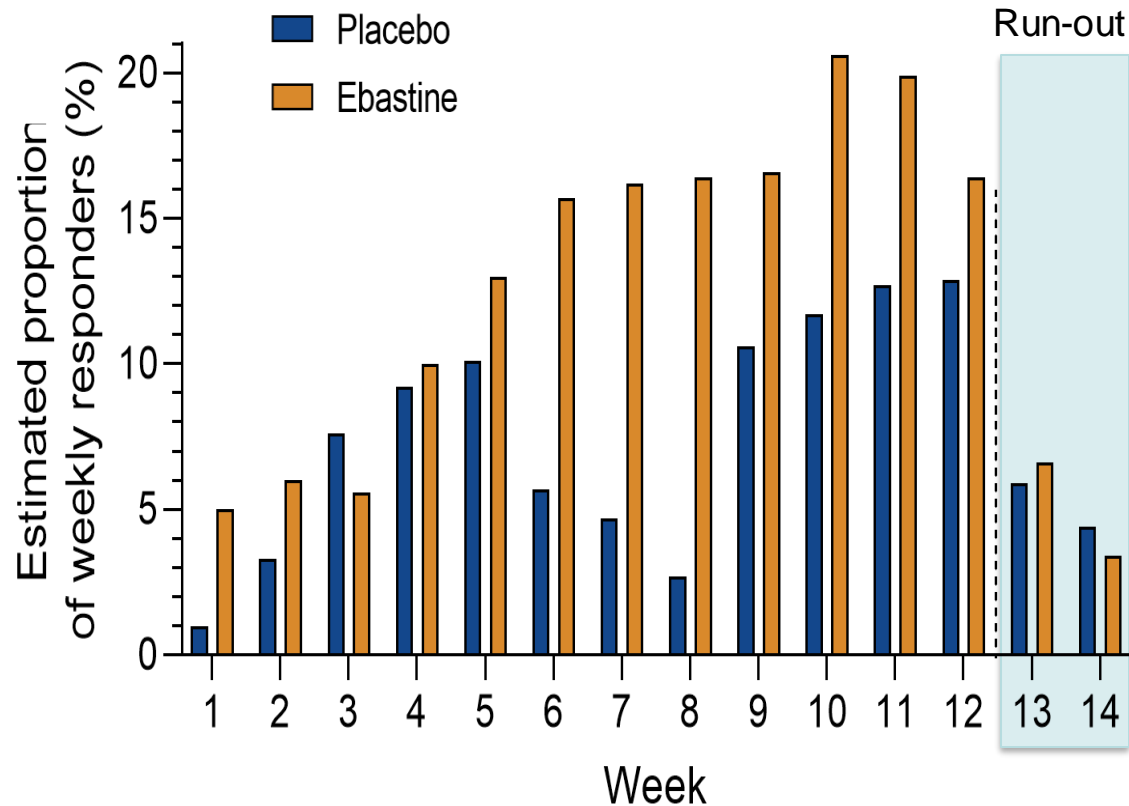
Aguilera-Lizarraga et al., Nature 2021



Wouters et al., Gut 2015

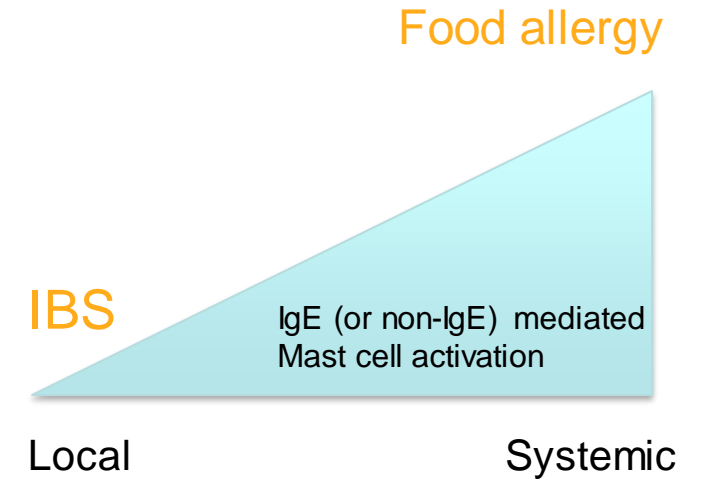
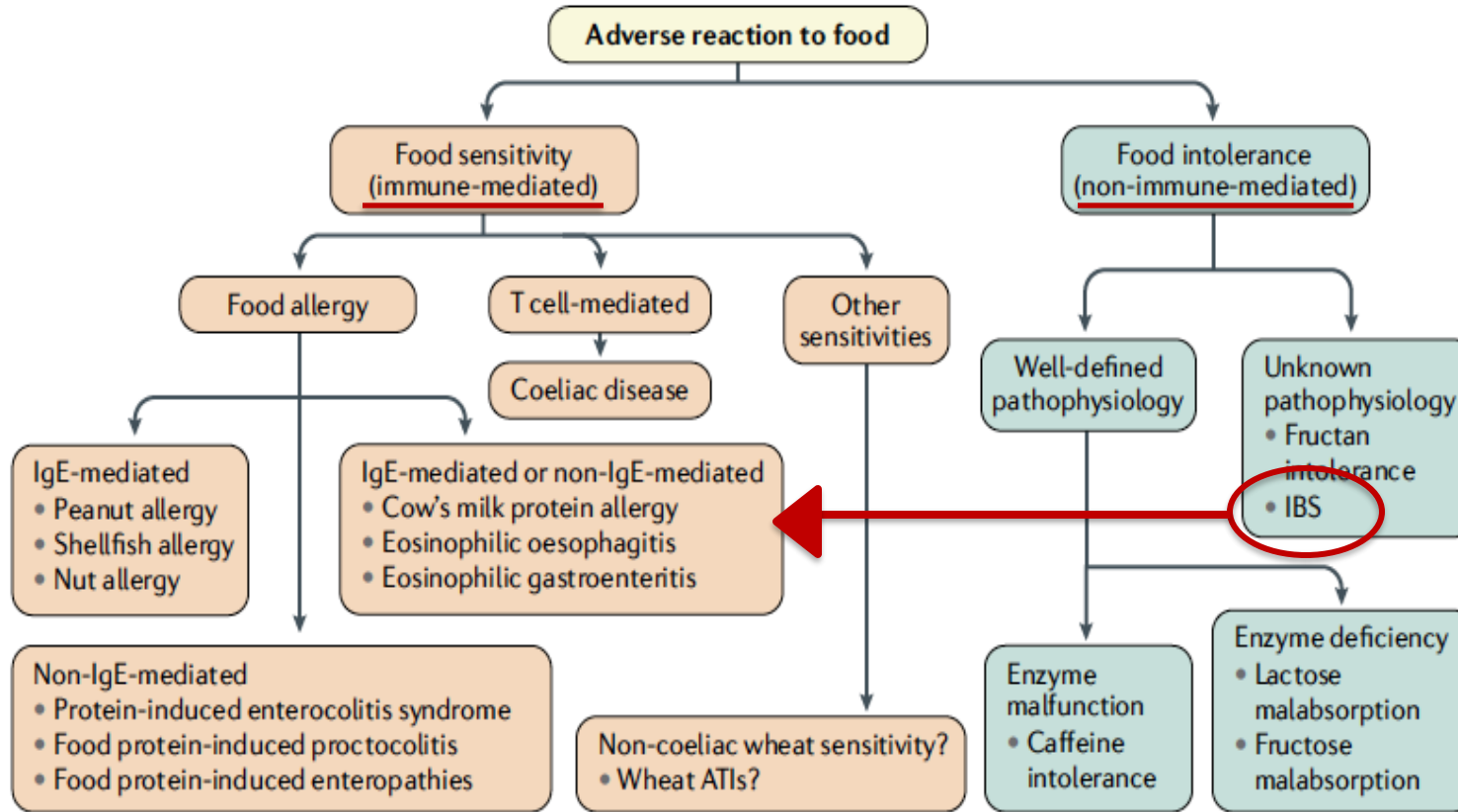
Effect of the H₁R antagonist ebastine on weekly global relief and abdominal pain in IBS

- Placebo-controlled randomized phase 2b trial
- 12 weeks H₁R antagonist ebastine vs placebo
- 203 non-constipated IBS patients Rome III



Adapted from Rothenberg, NEJM 2021

Food allergy, food sensitivity, food intolerance and ... IBS?



Acknowledgements



European Research Council
Established by
the European Commission



UZ Leuven
R. Bisschops
C. Breynaert
R. Schrijvers

KU Leuven
P. Vanden Berghe
I. Depoortere
R. Farre
J. Raes
K. Talavera
Y. Alpizar

Queen's University
(Kingston, Canada)
S. Vanner
D. Reed

University of Utrecht
F. Redegeld